

## MEMBERS NEWS

- An update from the American Association for Hand Surgery
- Obituary: Dr Jim Dobyns



# Remembering our Pioneers

**A tribute to the IFSSH founding fathers**

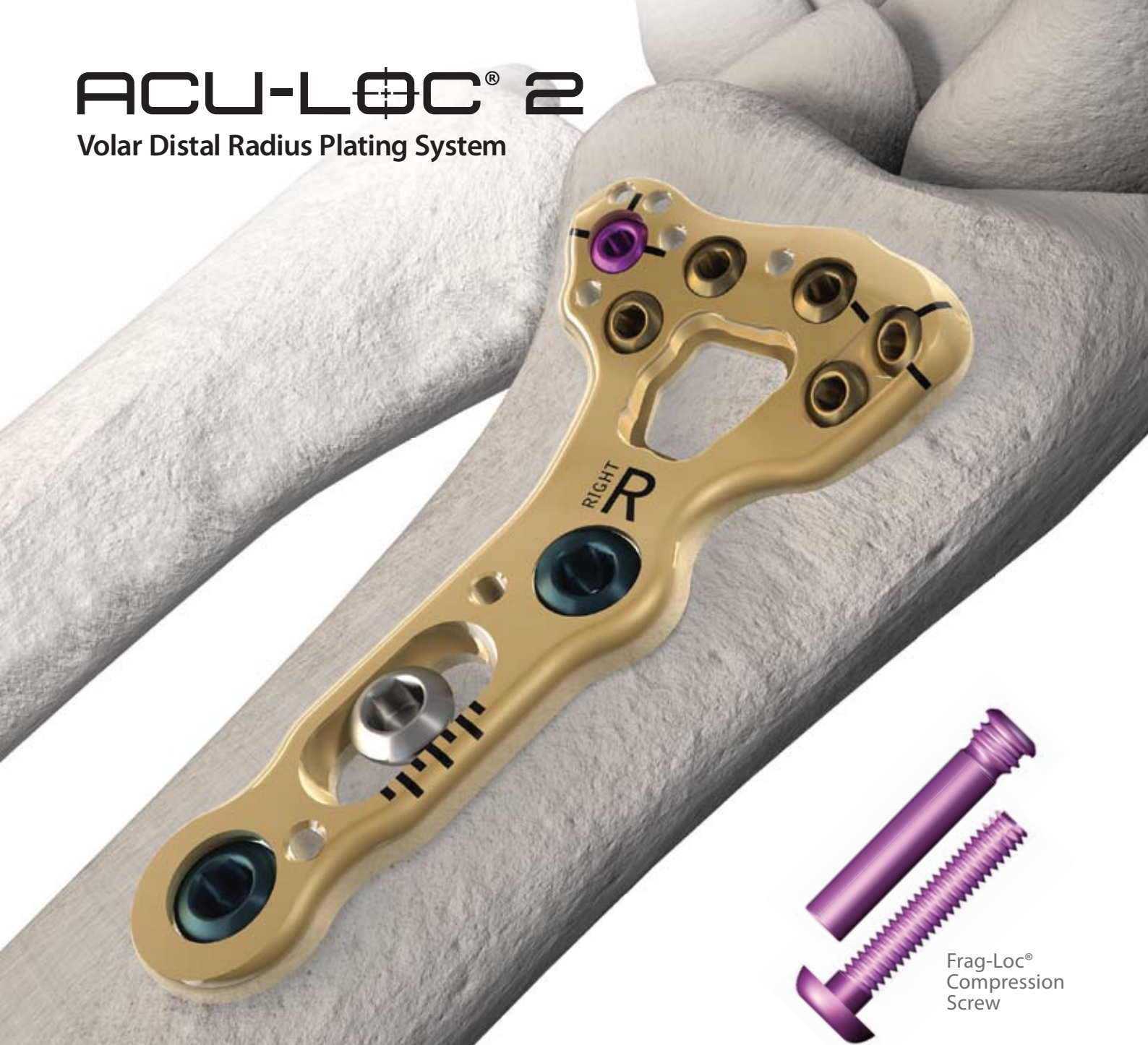**COMMITTEE REPORT:**  
HAND TRANSPLANTATION

**RESEARCH ROUNDUP:** INVESTIGATION  
SHINES NEW LIGHT ON BIPOLAR  
RADIAL HEAD ARTHROPLASTY



# ACU-LOC<sup>®</sup> 2

Volar Distal Radius Plating System



Frag-Loc<sup>®</sup>  
Compression  
Screw

## Introducing a Proximal Plate Option.

**MORE CHOICES, OPTIMIZED DESIGN, STREAMLINED SURGERY.**

Acumed<sup>®</sup> introduces the Acu-Loc<sup>®</sup> 2 Volar Distal Radius Plating System. This new system provides both proximally and distally fitting plates, fracture management instrumentation, innovative plate placement technology and the unique percutaneous Frag-Loc<sup>®</sup> compression screw for dorsal fragments. The Acu-Loc<sup>®</sup> 2 Volar Distal Radius Plating System is the most comprehensive wrist fracture solution on the market.



View Surgical  
Technique



Download  
Brochure



Visit Our  
Website



Contact Us

For more in depth product information including interactive 3D models visit [www.acumed.net](http://www.acumed.net) • (888) 627-9957 or visit us at ASSH booth #701.

**ACUMED<sup>®</sup>**



Back row left to right: **Paul Brand, Tamikazu Amako, Claude Verdan, Bill Littler, Erik Moberg and Martin Entin.**  
Front row, left to right: **Johan Landsmeer and Raoul Tubiana**

# Contents

---

## 4 Editorial

By Professor Ulrich Mennen, editor of the IFSSH ezine

---

## 6 Members news

Obituary: Jim Dobyns  
American Association for Hand Surgery

---

## 8 Letters

A letter to my hand therapist  
IFSSH Secretary-General Newsletter

---

## 10 Pulse

Congenital Committee Report  
Hand transplantation

---

## 20 Hand therapy

IFSHT Hand Therapy  
IFSSH Pioneers  
Remembering Pioneers in Hand Surgery

---

## 26 Research Roundup

Investigation shines new light on bipolar radial head arthroplasty  
Corrective wrist surgery makes patients with cerebral palsy happy

---

## 28 Journal Highlights

Tables of Contents from leading journals such as The American Journal of Hand Surgery, Journal of Hand Surgery Asian Volume, Journal of Hand Surgery European Volume and the Journal of Hand Therapy.

---

## 31 Product News

Osteomed – Hand Plating System  
Acumed – Acu-Loc2



# Editorial

Judging from the numerous requests from Hand Surgeons and Therapists to receive the IFSSH ezine, we can only deduct that this form of communication is welcomed, and serves a certain need. We plan to add the following features to future ezines:

## Remembering our Pioneers

At the Third IFSSH Congress held in Tokyo, Japan in 1986, it was decided to honour those who have made exceptional contributions to the body of hand knowledge which helps all of us to be more informed practitioners. This ceremony was repeated at the Fifth Congress in Paris, France in 1992, and at all subsequent meetings. We intend to place the names and brief biographical overviews of three to four Pioneers in every issue under the heading: "Pioneer Profile".

This edition will feature the "Introduction" to the first ceremony, written by Alfred Swanson. It also includes the names of the "Giants of Hand Surgery", i.e. those considered to be the founding fathers of our Specialty.

## Hand Therapy

Hand Surgery can hardly be performed without Hand Therapy. Many surgeons, especially in rural and outlying areas do not have the luxury of Hand Therapy. The intention is to feature a didactic section, to help us understand and demonstrate the art and science of Hand Therapy.



I hope you enjoy reading this issue as much as I enjoyed putting it together.

Prof. Ulrich Mennen  
President: IFSSH  
Editor: IFSSHezine

## IFSSH disclaimer

The IFSSH ezine is the official mouthpiece of the International Society for Surgery of the Hand. The IFSSH does not endorse the commercial advertising in this publication, nor the content or views of the contributors to the publication. Subscription to the IFSSH ezine is free of charge and the ezine is distributed on a quarterly basis. To subscribe, please click here. Should you wish to support this publication through advertising, please click here.

## IFSSH ezine editorial team

- Editor:** Professor Ulrich Mennen (*President of the IFSSH*)
- Deputy Editor:** Professor Michael Tonkin (*President-elect of the IFSSH*)
- Publication coordinator:** Marita Kritzingner (*Apex ezines*)
- Graphic Designer:** Andy Garside



# Obituary

On behalf of the IFSSH, we would want to add our sincere condolences to the family of Dr Jim Dobyms, who passed away on 14 July 2011.

Dr Dobyms was honoured as "Pioneer of Hand Surgery" by the IFSSH in recognition of his immense contribution to promoting Hand Surgery through his research, writing, teachings and especially as clinician.

## **Some of his notable achievements:**

- Appointed the third hand fellow in the New York Orthopedic program, directed by Robert E. Carroll, M.D.
- Publishing over 200 articles and textbook chapters covering the central themes of his hand surgery career
- Areas of expertise included: congenital hand and arm deformities, sports injury to the upper limbs and pain dysfunction of the upper limb
- Along with his long-time colleague Dr Ronald Linscheid, he specialised in all aspects of wrist area trauma, dysfunction and disease. Their pioneering work in wrist disorders led to thousands of articles and textbook chapters on the wrist
- Founded the International Wrist Investigator Workshop and supported the International Congenital Hand Surgery Group
- Served as president of the American Society for Surgery of the Hand in 1984
- He was honored as a Pioneer of Hand Surgery by the International Federation of Societies for Surgery of the Hand in 1998.



*Dr Jim Dobyms*

**Source:** *PostBulletin.com*

# American Association for Hand Surgery



Membership applications for the American Association for Hand Surgery are available online at <http://handsurgery.org/join>

Hand surgeons, residents, and hand therapists interested in advancing hand care are encouraged to join!

## **Benefits of membership include:**

- A subscription to HAND, the official Journal of the AAHS
- A subscription to the Association's Newsletter, Hand Surgery Quarterly, which keeps AAHS members up to date on the latest news in hand surgery and hand therapy
- Access to research grant funds
- Opportunities to present your work at AAHS Annual Meetings to audiences of well-respected professionals in hand surgery and hand therapy
- Access to the Members Only area of the AAHS website, which provides you with secure AAHS documentation, including access, contact information and areas for expertise of Association members; membership alerts; access to HAND, and more
- Opportunities to influence the future of the profession through the AAHS
- Reduced registration rates to AAHS educational programs and all Association-sponsored products and services

**Visit <http://handsurgery.org/join> to become a member of AAHS!**



hand plating system

# versatile SOLUTION for COMPLEX fractures

## Only system with:

- Patented subcondylar plate
- Ability to use a cannulated screw through the plate
- Up to 22 degrees of variable angle locking
- 5 different screw options



visit us at [www.osteomed.com/hps](http://www.osteomed.com/hps)

3885 Arapaho Road, Addison, Texas 75001 • Customer Service: 800.456.7779 • Fax: 800.390.2620 • [www.osteomed.com](http://www.osteomed.com)

# A letter to my Hand Therapist

*Dear C,*

What if, one day you have to treat a patient with a transplanted hand?

What if after the initial excitement of receiving the hand, the recipient is not happy with the new hand? Unlike a transplanted kidney, heart or liver which one will never see or touch, the new hand will always be seen, will always be felt, will look different (in size, shape, texture, colour), will smell different and even taste different. It will always feel different and 'do' different. Even the nails will not grow like his own. The skin will tan differently in the sun. Will this new hand ever become his 'own' hand, or will it be 'the other guy's' hand, the 'third' hand. This 'hand-on-loan' will have its own character. Can the adopted hand ever become part of the host body-image?

What if tissue memory interferes with therapy? Does the patient experience the same sensory awareness (light touch, deep touch, pain, temperature, vibration, proprioception, two-point-discrimination, stereognosis) with the new hand? Will he experience past feelings of the donated hand and may this reveal experiences the donor's spouse was not aware of? Will the recipient suffer from mixed feelings? When he touches his spouse with the 'other' hand, what will he feel and more importantly, what will his spouse feel?

What if the recipient receives another dominant hand? Will he be doubly-dominant? Will there be competition between the dominant hands? Will the brain capabilities be enhanced by the new sensory input?

What if a skilled hand is transplanted? Will the recipient benefit from the potential dexterity? Where is 'skill' centered: in the hand, in the brain or both? If any skills are remnant in the hand, surely the recipient receives an added bonus like being able to play the piano or deal cards?

What if a conflict between 'transplanted life' and recipient life occurs? Does the new hand relinquish its life energy in favour of its new master? Is this conflict not one of the unrecognised causes why transplanted tissue is rejected and therefore so difficult to control?

What if the new owner likes his third hand but suffers from the numerous side effects of immunosuppression such as kidney failure, cancer, GI disturbances etc.?

What if photographs and video clips are compared before and after transplantation: "see, it worked better and looked better with the original owner"

What if the donor's spouse demands visitation rights? Do body-parts of the donor form part of the estate of the deceased or the inheritance? Is the hand donated, loaned or simply just given away?

Just some thoughts!

*With sincere regards, U.*



# IFSSH Newsletter – June 2011

## 2011 Delegates' Council Meeting

Six months have passed since the Seoul 2010 IFSSH Congress and it is time to renew our energy and focus our thoughts on future IFSSH plans. Requests, new ideas and projects are to be planned and discussed, and all IFSSH member nations are invited to be a part of this process. The annual IFSSH Delegates' Council Meeting provides the forum for this opportunity.

The 2011 IFSSH Delegates' Council meeting will be held in conjunction with the annual congress of the American Society for Surgery of the Hand (ASSH) in Las Vegas. The programme is now available and the Delegates' Council Meeting will be held on Thursday 8th September, 11:30am.

More information regarding the ASSH Congress (September 8-10) is available at [www.assh.org/AnnualMeeting](http://www.assh.org/AnnualMeeting). On-line registration has opened on the website and on-site registration is available from Tuesday 6th September.

In order to have a successful meeting we need two important factors:

Firstly, we need the active participation of all societies, as only with the presence of the delegates of all societies will our discussions and decisions reflect the opinions, will and priorities of the international hand surgery community. If your Society's IFSSH Delegate cannot attend the meeting personally, please advise the secretariat ([administration@ifssh.info](mailto:administration@ifssh.info)) of an alternate member of your society who will be present.

Secondly, we need to ensure that our meeting is well prepared. We must

efficiently discuss many matters and, as always, one meeting is rarely enough time to do so without prior preparation. For this we need to have your thoughts, ideas, requests and plans in due time to include them in the agenda. We would appreciate if everybody who has something to say, something to ask, or something to suggest could send us these intentions by e-mail for inclusion in the agenda.

The full details and agenda/documents for the IFSSH Delegates' Council Meeting will be forwarded to all Delegates' before the meeting.

The IFSSH Executive look forward to seeing IFSSH Delegates and Congress participants in the USA in September when we join the annual ASSH meeting.

### Ezine

The second issue of the IFSSH ezine was published in May by the President of IFSSH, Ulrich Mennen. Both the scientific content and format of this publication are outstanding and we congratulate Ulrich on this initiative. We hope that many thousands of hand surgeons around the world enjoy reading the ezine.

### FESSH Congress, Oslo 2010

A successful FESSH congress was held in Oslo, May 25-28 2010. The Congress attracted more than 1300 hand surgeons and hand therapists, mainly from Europe, but also from North America, the Asia-Pacific, South America and Africa. The Congress provided well organised scientific and social programmes, and these, along with the high number of exhibitors and workshops, resulted in an



interesting meeting.

Congratulations to the organisers of the Oslo Congress. We look forward to a meeting of equal quality when our Belgian colleagues host the 2012 Antwerp FESSH Congress.

### Bursaries and Grants

Bursaries and grants are available for worthy projects that fulfil the criteria for the use of IFSSH funds. All member societies are welcome to submit proposals to apply for a bursary or congress assistance grant. The guidelines and criteria can be found on the website. Applications should be submitted to the Secretary-General ([secretary@ifssh.info](mailto:secretary@ifssh.info)) for consideration by the Executive Committee.

### IFSSH website

The IFSSH website ([www.ifssh.info](http://www.ifssh.info)) is continually updated with society details. If your society wishes to place details of its annual meeting on this website, please also inform the secretariat and include details of the dates, location and website/email for enquiries.

### Future Meetings

A detailed list of national and regional hand surgery meetings is available on the IFSSH website. The triennial IFSSH Congresses are as follows:

**XIIth IFSSH - IXth IFSHT Congress** - New Delhi, India. 4th - 8th March, 2013

**XIIIth IFSSH - Xth IFSHT Congress** - Buenos Aires, Argentina, 2016

*Yours sincerely,*

**Zsolt Szabo**

**Secretary-General, IFSSH**

# Congenital Committee Report

## IFSSH Congress - Seoul, 2010

Present: T. Ogino, R. Habenicht, T. Light, M. Tonkin

Apologies: L. De Smet, M. Ezaki, A. Ladd

### 1: Congenital Limb Anomalies – Scott N. Oishi, Marybeth Ezaki

#### 1. The problem

The child born with a noticeable anomaly has been the focus of enormous natural curiosity throughout recorded history. These special children have been regarded as monsters in many societies, and as gods or goddesses in others. Cultural and religious views determine whether these children are accepted or reviled.

Whereas in the past these children were hidden away from the public, today children with special needs are included in schools, and supported with

reasonable adaptations and focused therapy services mandated by the laws of many countries. Happily, today the birth of a child with a limb anomaly in the United States and developed nations is seen not as a curse, but as a condition that has a natural explanation. Most children with congenital upper limb anomalies have normal cognitive function, and therefore, have the potential to both understand and overcome their differences and to be productive members of our communities. Our society has come to accept these children, to recognize their needs, and to celebrate their successes.

Congenital anomalies of the upper limb present enormous challenges for the child, the parents, the family and the professionals caring for the child. In addition to the clinical findings that define and characterize the abnormal morphology of the upper limb, important aspects of evaluation and treatment must be directed to the identification of associated syndromes and anomalies, and the emotional and educational support of the parents and family. Later issues that must be addressed include all the adaptations that contribute to functional independence, an intact self-esteem, and psychological health for the child herself.



The problem that we, as hand surgeons, are faced with is how to best use our skills and knowledge to enhance the ability of any given patient to function in society. How can we know and do what is the best for the child.

## 2. The solution

Establishing an accurate and complete diagnosis is a team effort. Most of these small patients are treated at referral centers where expert care is available for the whole child. A network of dedicated pediatric orthopaedic hospitals was established by numerous benevolent organizations in the United States, initially to provide free care to the children crippled by poliomyelitis in the last century. Today, the Shriners Hospitals, the Scottish

Rite Hospital for Children, and others with the same mission, continue to provide this care for children with orthopaedic needs. The upper limb surgeons from these hospitals have organized meetings for the collegial exchange of information as well as informal networking and referral of complex patients. Numerous publications have come from these collaborations.

The Hand Surgeon must be aware of the potential for associated anomalies and may be the one to initiate the appropriate referrals. With the hand surgeon should reside the knowledge to know what to look for, especially as education in the primary care specialties devotes little or no time to most of these obscure conditions.

Help must also be made available to educate and support the parents in the critical bonding with their

infant, especially if the diagnosis of the congenital anomaly was not made before birth. Divorce is a very common response to the birth of a child with a congenital limb anomaly because of the added stress on the marriage. The child herself will experience a normal grieving process when she is old enough to understand the full impact of having a limb anomaly. Family and caregiver support systems must be robust to nurture a child through these transition periods with a valued sense of self.

Care of the child with a congenital anomaly is complex and rewarding, and must be long term and ongoing. Enabling a child to interface with the environment and become more independent must be the goal of any treatment. The guiding principle of "To-For" in deciding whether an operation is indicated, recognizes that there are many things that we can do "To" the child, but we must make sure that what we do is truly "For" the child.

Amazing advances in surgical technique have added immensely to our ability to reconstruct and improve the lives of our patients. The judgment to know which child will benefit from microsurgical free toe transfers, or from the application of limb lengthening techniques is more difficult to learn. Where is the evidence? *Primum non nocere*

Children with congenital anomalies of all sorts will continue to be born as the result of genetic mutation, or genomic variation, epigenic effects, and teratogenic causes. Advances are being made, at an ever increasing rate, that define the basic science of the causes of congenital anomalies. The understanding of molecular

## ERRATUM:

■ The article titled 'A New Classification of Congenital Anomalies of the Hand and Upper Limb' presented in Issue 2 of the IFSSH ezine was incorrectly labelled as a report from the IFSSH Congenital Committee. This Scientific Committee has not yet considered the details of this new classification but will do so in the period leading up to the IFSSH Congress in India in 2013.

The report prepared by the Committee and presented at the 2010 IFSSH Congress in Seoul is presented in this, the third IFSSH ezine issue.

The Editors apologise to Professor Ogino, Chairman of the Committee, and its members for this error.

**Ulrich Mennen**

Editor

**Michael Tonkin**

Deputy Editor

mechanisms of causation may someday lead to the ability to prevent or alter final outcomes for children – but in the distant future. Not all of these anomalies will be predicted or prevented. We must continue to ask questions and ensure that our communities support research in the areas of congenital anomalies. We must, likewise, work toward ensuring a clean and healthy environment for the children of our children.

We must also recognize and fight the discrimination that comes from ignorance and ill-focused blame and guilt. Innocent curiosity that changes into schoolyard teasing, can easily change into deeply wounding harassment if we do not address current societal values about limb malformations. Because of our unique role in the lives of these children, we are able to ask the questions that will uncover these problems. “Does your hand ever make you sad?” “Who is your best friend?” “Draw a picture of yourself.” Early intervention with psychological support and peer groups is more critical than any surgical procedure we can do. Social networking is an important aspect of support for our patients. In the United States camps, retreats, websites, handouts, and peer support offer enormous benefits for the children and the families, with equal feedback and immense personal reward for the surgeon who chooses to become involved in these efforts.

As hand surgeons, we must perform a critical analysis of our own results and honestly report them so that we can move the science and care of the children forward. Congenital hand anomalies are unusual and our

natural curiosity makes us eager to try a procedure that has appeared in the textbook. Long term follow-up and outcomes assessment of how we impact Quality of Life are much more important than short term measures of pinch and grip, and must become an integral part of what we do.

Many hand surgeons – too many to name – have contributed to the knowledge we have about congenital anomalies. National and international meetings provide opportunities to exchange information and updates. At these meetings, the name of the nation is “Science,” a land with no borders, and our anthem must be “For the Children.” Translational research that brings clinicians and basic scientists together will greatly expand our knowledge in this century. Rapid exchange of information and electronic consultation benefit us as well as our patients.

The future is bright for the field of congenital hand surgery. We must constantly remember to put the best interest of our patients first, and to follow and support them to the other side of their childhood.

(The manuscript above has been written by Dr. Marybeth Ezaki and Dr. Scott N. Oishi for the chapter for the IFSSH book, *Hand Surgery – Worldwide: International Reconstruction of a “Beautiful and Ready Instrument of the Mind”*. Dr. Urbaniak, who is a President of the IFSSH, allowed us to use it as our committee report.)

## 2: Upper Limb Hypertrophy

The Committee discussed the appropriate diagnostic name for hyperplasia of the hand and upper limb with aberrant muscles. This condition is characterised by muscle hyperplasia, aberrant muscles or accessory muscles, ulnar drift of the fingers at the metacarpophalangeal joints, flexion contractures of the metacarpophalangeal joints, extension contractures of the wrist, and enlargement of the spaces between the metacarpals. The Committee proposes the descriptive term “aberrant muscle syndrome” or “accessory muscle syndrome” for this condition.

## 3: Triphalangeal thumb

A small accessory middle phalanx in the skeletally immature may have a joint both proximal and distal to the accessory phalanx (type A). Alternatively there may be a cartilaginous connection between the accessory middle phalanx and the epiphysis of the terminal phalanx, which is not obvious radiologically in the skeletally immature (type B). Following completion of ossification, type A will proceed to a mature and separate middle phalanx (type D). However, type B will mature into a triangular epiphysis with no joint between the middle phalanx and terminal phalanx.

The Committee agrees that types B and C are part of the spectrum of thumb triphalangism.

# Hand Transplantation

## IFSSH Report 2010

Steven L. Moran, MD\*, Professor and Chair of Plastic Surgery, Professor of Orthopedics, Surgical Director VCA Program, Mayo Clinic, Rochester, MN

\*Corresponding author. 200 First Street SW, Rochester MN 55905, (507) 284-4685 Email: moran.steven@mayo.edu

### Introduction

Over the past decade, hand transplantation has become an established means of limb reconstruction for patients with severe injuries to the hand and forearm. Hand transplantation, like face transplantation, is a form of vascularized composite allotransplantation (VCA). Similar to solid organ transplantation, VCA consists of the transfer of living tissue from a donor to the recipient. The patient requires standard immunosuppression to prevent rejection. Unlike solid organ transplantation, nerve regeneration into the transplanted tissue is required for sensation within the skin and re-animation of muscles within the transplanted tissue. . Since 1998 over 60 hand transplants have been performed successfully around the world. This manuscript will provide a brief overview of the current state of hand transplantation .

### Background

The first attempt at hand transplantation occurred in Ecuador in 1964 by Gilbert but failed due to problems with inadequate immunosuppression.[5, 6] Over the past 2 decades immunosuppressive

medications have substantially improved with the development of calcineurin inhibitors, FK-506 (Tacrolimus) and mycophenolate mofetil (MMF). These medications have allowed for improvement in solid organ transplantation and for long-term survival of limb transplant models in animal models.[7-9] Since 1998 a worldwide registry was created to track patient progress following VCA and report outcomes.[12].

### International Registry of Hand and Composite Tissue Transplantation (IRHTCC)

The most extensive and comprehensive outcome data regarding hand transplantation was published by the International Registry of Hand and Composite Tissue Transplantation (IRHTCC) in 2010. At that time, follow-up was available on 33 patients who had undergone 49 hand transplants (17 unilateral and 16 bilateral transplants) and 2 digits. Patients who have elected to undergo hand transplant have tended to be younger individuals, with an average age of 32 years (range 19–54 yrs). Follow-up within the IRHTCC report extended from 1 months to 11 years.[13, 14] The majority of patients were male. Time from original injury

to transplant varied from 2 months to 34 years[13]. The cause of the majority of amputations has been trauma. Within the IRHTCC study, graft survival was 100% at 1 and 2 years following transplantation[12].

Within the European and American experience, current long-term graft survival is better than 94%. Immunity-mediated rejection has been the primary cause of graft loss. [12, 14]. The first case of graft loss occurred with the first unilateral hand transplant patient in 1998; pathologic specimens of the rejected hand showed evidence of lichenoid like lesions, which can also be seen in cases of graft versus host disease[12, 13]. The rejection occurred after the patient stopped taking his immunosuppression medications despite a well-functioning hand. The second case of graft loss occurred in an American patient transplanted in Louisville as a result of chronic rejection. The cause of the American patient's rejection is thought to be related to fibro-intimal hyperplasia, a mechanism of rejection which can be seen in cases of heart transplant rejection[15].

The choice of immunosuppression has been an issue of some debate but the majority of hand transplant procedures have involved an induction

process consisting of antithymocyte globulin (ATG), tacrolimus, MMF and steroids. Maintenance therapy for the majority of patients has been continuation of MMF, tacrolimus and steroids; this triple drug combination is similar to what is currently used as standard treatment in solid organ transplantation[12, 16, 17]. Modifications of this triple therapy have been reported, and in the IRHTCC study, 21.7% of recipients received only steroids and tacrolimus for maintenance therapy, whereas 8.7% of recipients were switched to sirolimus; 8.7% of recipients received steroids, low dose tacrolimus, and everolimus, 4.3% received sirolimus and MMF. 13% of patients underwent withdrawal of steroids at some point during the follow-up period[12, 13]. Substitutions for tacrolimus (to sirolimus or everolimus) are usually related to the patient's tolerance to the medication.

The desire for minimizing steroid dosing in these patients is related to the unwanted side effects of the medications. Cushing syndrome, weight gain, dermatitis and mood swings have also been observed and have been attributed to the use of steroids. Metabolic complications have been seen in up to 50% of patients and have included hyperglycemia and increase in creatinine values. Most of these adverse effects have been transient and reversible. One patient has required bilateral hip joint replacements; however, at the time of the IRHTCC study all patients' serum creatinine levels were inferior or equal to 1.4mg/dL (eight recipients inferior or equal to 1 mg/dL). At this time point

no malignancies or life-threatening conditions have been reported[12, 13].

The majority of patients (87%) have developed opportunistic infections which include CMV, Clostridium, and herpetic infections. The incidence of metabolic complications and opportunistic infections appears to be similar to that of solid organ transplantation. Newer protocols of steroid tapering or steroid sparing therapies have been tried in addition to new antilymphocytic agents, but it is still too early to assess any benefit of these protocols over "standard immunosuppression." [12, 18].

Despite immunosuppression, acute rejection episodes occurred in 85% of the patients within the first year; however all episodes of acute rejection were controlled with modifications of immunosuppressive medications. Acute rejection, in cases of hand transplantation, is evaluated with the use of skin biopsies. Rejection episodes are usually heralded by the development of a rash or dermatitis, alerting the patient to seek medical attention. Skin biopsies show evidence of lymphocytic infiltration in cases of acute rejection. Rejection episodes and their management are similar to those of solid organs and appear to have better survival rates than solid organs when immunosuppressive protocols are followed properly[18, 19]. The majority of acute rejection episodes may be managed with the use of topical or systemic steroid and topical tacrolimus[12]. Deterioration in hand function has not been noted following rejection episodes. [12, 17]

Functional outcomes have been

very encouraging with all patients recovering protective sensibility, 90% recovering tactile sensibility, and 82.3% recovering discriminative sensibility[14]. Muscle recovery begins with the extrinsic flexor and extensor groups, allowing some patients to perform grasp and pinch activities shortly after transplantation. Recovery of intrinsic muscles can take up to 9 and 15 months post transplantation. Recovery of intrinsic muscle function has been confirmed by electromyographic studies in several hands[16, 19]. Extrinsic and intrinsic muscle function has allowed patients to perform most daily activities, including eating, driving, grasping objects, riding a bicycle or motorbike, shaving, using the telephone and writing. Patient quality of life scores improved significantly in more than 75% of the recipients. Bilateral hand transplanted recipients were only slightly more satisfied than unilateral hand transplant patients. Returning to work has been a consistent feature for the majority of the patients[13, 17]. [14] Functional MRI has demonstrated that after transplantation, hand representation is regained within the sensory and motor cortex within the brain[20, 21].

Brandacher and colleagues reported that the most significant clinical improvements occur during the first three years following transplant, with minor improvements occurring after that. Discriminative sensation has been identified in all forearm transplantations and gives great hope to patient with very high disabling injuries[17]. Nerve recovery in traumatic injuries is thought to recover at a rate of 1 mm a

day from the point of injury. Thus the more proximal the transplantation the longer the time required to recover sensation within the hand. Interestingly, it has been noted that tacrolimus, one of the immunosuppressive medications commonly used in hand transplantation, has been able to accelerate nerve recovery, potentially shortening the period of time necessary for sensory return within the hand[22].

In summary, the IRHTCC report shows that after 9 years of clinical follow-up hand transplantation is technically feasible and that results are encouraging. Major adverse effects because of immunosuppressive medications did not occur. Immunosuppressive protocols currently used in solid organ transplantation turned out to be sufficient to prevent rejection after hand transplantation. From a functional point of view, a remarkably good recovery of sensibility has been documented in all transplanted hands. In particular, protective sensation was achieved in all patients within 6 to 12 months and, as time progressed, 90% showed tactile and 72% of the discriminative sensibility, thus providing a true benefit over prosthetic wear[12, 13].

## References

1. Clark, D.P., Scott, R.N., Anderson, I.W., Hand problems in an accident and emergency department. *J Hand Surg*, 1985; 10B: 297-299.
2. Malt, R.A., McKhann, C.F., Replantation of severed arms. *JAMA*, 1964; 189: 716-22.
3. Tamai, S., Twenty years' experience of limb replantation: review of 293 upper extremity replants. *J Hand Surg*, 1982; 7: 549-56.
4. Kamatsu, S., Tamai, S., Successful replantation of a completely cut-off thumb: case report. *Plast Reconstr Surg*, 1968; 42: 374.
5. Gilbert, R., Transplant is successful with a cadaver forearm. *Med Trib Med News*, 1964; 5: 20-2.
6. Gilbert, R., Hand transplanted from cadaver is reamputated. *Med Trib Med News*, 1964; 5: 23-5.
7. Goto, T., KIno, T., Hatanaka, H., et al., Discovery of FK-506, a novel immunosuppressant isolated from *Streptomyces tsukubaensis*. *Transplant Proc*, 1987; 19: 4-8.
8. Allison, A.C., Eugui, E.M., Immunosuppressive and other effects of mycophenolic acid and an ester prodrug, mycophenolate mofetil. *Immunol Rev*, 1993; 136: 5-28.
9. Jones, J.W., Ustuner, E.T., Zdichavsky, M., et al., Long-term survival of an extremity composite tissue allograft with FK506-mycophenolate mofetil therapy. *Surgery*, 1999; 126: 384-8.
10. Murray, J.E., Organ transplantation (skin, kidney, heart) and the plastic surgeon. *Plast Reconstr Surg*, 1971; 47: 425-31.
11. Dubernard, J.-M., Owen, E., Herzberg, G., et al., Human hand allograft: report on first 6 months. *Lancet*, 1999; 353: 1315-20.
12. Lanzetta, M., Petruzzo, P., Dubernard, J.-M., Margreiter, R., et al., Second Report (1998-2006) of the International Registry of Hand and Composite Tissue Transplantation. *Transplant Immunol*, 2008; 18: 1-6.
13. Petruzzo, P., Lanzetta, M., Dubernard, J.-M., Margreiter, R., et al., The International Registry on Hand and Composite Tissue Transplantation. *Transplantation* 2008; 86: 487-492.
14. Petruzzo, P., Lanzetta, M., Dubernard, J.-M., et al., The International Registry on Hand and Composite Tissue Transplantation. *Transplantation*, 2010; 90: 1590-1594.
15. Michaels, P.J., Espejo, M.L., Kobashigawa, J., et al., Humoral rejection in cardiac transplantation: risk factors, hemodynamic consequences and relationship to transplant coronary artery disease. *J Heart Lung Transplant*, 2005; 22: 58-69.
16. Dubernard, J.-M., Petruzzo, P., Lanzetta, M., et al., Functional Results of the First Human Double-Hand Transplantation. *Ann Surg*, 2003; 238: 128-136.
17. Brandacher, G., Ninkovic, M., Piza-Katzer, H., et al., The Innsbruck Hand Transplant Program: Update at 8 Years After the First Transplant. *Transplantation Proc*, 2009; 41: 20-2.
18. Breidenbach, W.C., Tobin, G.R., Gorantla, V.S., et al., A position statement in support of hand transplantation. *J Hand Surg*, 2002; 27: 760-70.
19. Breidenbach, W.C., Gonzales, N.R., Kaufman, C.L., Klapheke, M., et al., Outcomes of the First 2 American Hand Transplants at 8 and 6 Years Posttransplant. *J Hand Surg* 2008; 33A: 1039-1047.
20. Giroux, P., Sirigu, A., Schneider, F., et al., Cortical reorganization in motor cortex after graft of both hands. *Nat Neurosci*, 2001; 4: 691.
21. Vargas, C.D., Aballéa, A., Rodrigues, E.C., et al., Re-emergence of hand-muscle representations in human motor cortex after hand allograft. *Proc Natl Acad Sci*, 2009; 106: 7197-202.
22. Gold, B.G., FK506 and the role of immunophilins in nerve regeneration. *Mol Neurobiol*, 1997; 15: 285-306.
23. Klapheke, M., The role of the psychiatrist in organ transplantation. *Bull Menninger Clin*, 1999; 63: 13-39.
24. Klapheke, M., Transplantation of the human hand: psychiatric considerations. *Bull Menninger Clin*, 1999; 63: 159-73.
25. Siegler, M., Ethical issues in innovative surgery: should we attempt a cadaveric hand transplantation in a human subject? *Transplant Proc*, 1998; 30: 2779-82.
26. Simmons, P.D., Ethical considerations in composite tissue allotransplantation. *Microsurgery*, 2000; 2000: 458-65.

IFSSH 2010 SEOUL  
13th Triennial Congress of the International Federation of  
Societies for Surgery of the Hand  
October ~ 4 November 2010 Sheraton Grand Walkerhill Hotel, Seoul, Korea



## For the members by the members...

The **IFSSH ezine** is created with the intention of engaging the global hand surgery community and to promote the profession through the sharing of knowledge.

In order for the IFSSH ezine to remain relevant and topical, we rely on you, our readers, to:

- Subscribe to receive the ezine  
FREE OF CHARGE 4 times per year
- Submit letters to the editor
- Provide us with feedback about the ezine

**CLICK HERE**

TO COMPLETE A  
5 MINUTE SURVEY  
ABOUT THE  
IFSSH EZINE

# IFSSH ezine archive

To view the previous issues of the IFSSH ezine, you can access the archives in one easy place:

**CLICK HERE**



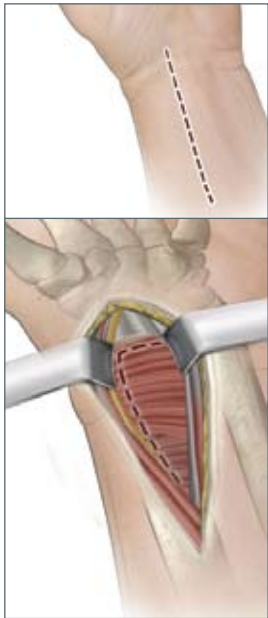
The **IFSSH ezine** is the fastest growing online community of hand surgeons around the world.

**Join us today!**

**SUBSCRIBE FOR FREE!**

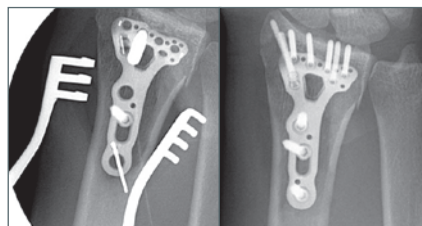
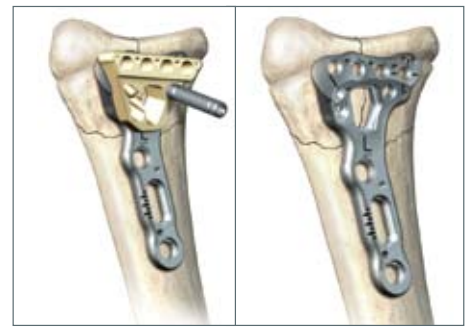
## 1 EXPOSURE

The patient's forearm is supinated to expose the surgical site. To maximize exposure, a towel is placed under the wrist, supporting it in extension. Make a longitudinal incision approximately six centimeters in length just radial to the FCR tendon to protect against injury to the palmar cutaneous branch of the median nerve. The sheath is opened and the FCR tendon is retracted radially to protect the radial artery. The FPL is identified by passive flexion/extension of the thumb interphalangeal joint and is retracted ulnarly to protect the median nerve. Next, the pronator quadratus is identified by its transverse fibers and is released radial to ulnar to expose the fracture site.



### the radial shaft.

**Note:** The Plate Positioning Handle can be utilized at this time for plate placement. (Please refer to Page 8 for assembly and technique)



### Styloid Positioning Post:

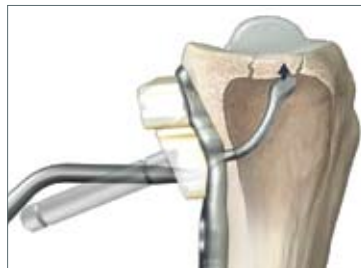
(Image A) To confirm A/P plate placement, a radiopaque

positioning post is utilized in an A/P view to project the trajectory of the most distal styloid screw. To evaluate styloid screw placement, position the wrist under fluoroscopy in an A/P view and adjust the plate so that the positioning post targets the styloid tip. This verifies correct trajectory of the styloid screw prior to drilling.

**Note:** The K-wire can also be used to verify screw trajectory by inserting the K-wire guide into the bone through the targeting guide K-wire holes.

## 2 FRACTURE REDUCTION

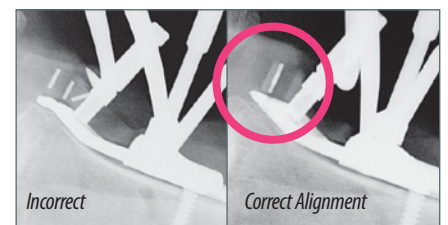
The brachioradialis may need to be released from its insertion on the radial styloid to facilitate reduction and visualization of the fracture. Reduce the fracture using manual techniques; provisional stability can be achieved with K-wires and evaluated under fluoroscopy.



**Fragment Reduction Tool:** A unique tool designed specifically for distal radius surgery can be used for articular reconstruction. A broad mallet and narrow thin tip provide the ability to lift and position articular fracture fragments through the plate window when possible.

### Distal Screw Row Positioning Posts:

(Image B) To confirm M/L plate placement, and K-wire placement, line up the two parallel



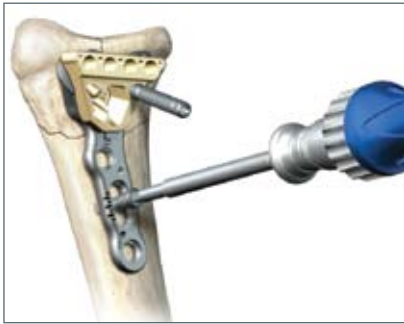radiopaque posts in an M/L view. A single plane is created by the goal posts beneath the subchondral bone, showing the trajectory of the distal screw row. If the aligned goal posts do not target into the joint, then the distal screw row will not either. This M/L fluoroscopic view can be achieved by lifting the hand in neutral rotation so that the forearm is 20° to the surgical table. The K-wire holes are also in line with the posts and distal screws of all Acu-Loc® 2 distal radius plates, allowing the surgeon to verify screw placement. The plate's position is then secured proximally with a .054" K-wire or plate tack and distally with a .054" K-wire.

## 3 PLATE PLACEMENT

The plate is made to sit along the distal aspect of the radius to support articular fracture fragments. Once the appropriately sized plate is selected, attach the corresponding targeting guide using the locking bolt. The cannulated locking bolt is threaded into the proximal ulnar 2.3 mm screw hole. **The plate should be placed parallel to**

## 4 PROXIMAL SCREW PLACEMENT

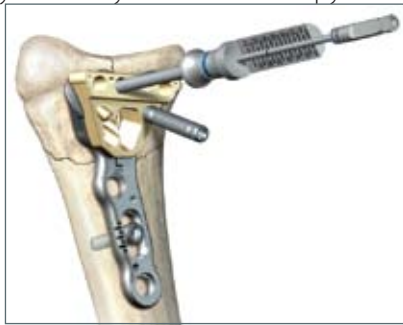The first screw to be placed is a 3.5 mm nonlocking cortical screw through the slot in the plate. Using the 2.8 mm drill and the drill guide, drill to the far cortex. Drill



depth is then measured with the depth gauge. Insert a silver 3.5 mm nonlocking screw. The screw may need to be downsized after the plate has been reduced down to the bone.

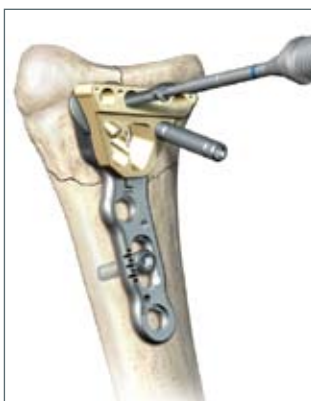## 5 DISTAL SCREW HOLES

Utilizing the radiopaque positioning posts in the targeting guide, the position of the plate relative to the radio-carpal articular surface can be fine tuned by sliding the plate proximally or distally under fluoroscopy. If the radiopaque posts don't target the joint, the distal K-wires and 2.3 mm screws will not either. To further assess the position of the distal 2.3 mm screws relative to the radio-carpal articular surface, place a .054" K-wire through the one of the K-wire holes in the targeting guide closest to the joint and assess its location under fluoroscopy.



Upon satisfactory reduction and anatomic fit, insert the drill guide into one of the distal screw holes and drill using the 2.0 mm drill. Measure screw length by using the laser mark on the drill or depth probe against the scale on the drill guide.

**Note:** Screw insertion of the proximal ulnar 2.3 mm hole should be performed after all other distal 2.3 mm screws are placed. Drilling can be performed through the locking bolt. Remove the locking bolt and utilize the drill guide and depth probe to measure screw length.



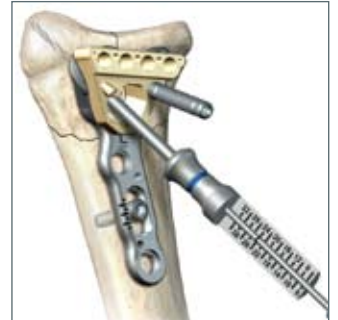
**Distal Screw Options:** There are four options of 2.3 mm screws that can be used distally: Fully Threaded Locking Screws (gold), Smooth Locking Pegs (bronze), Non-Toggling Screws (silver), and the Frag-Loc® Compression Screw (see page 9 for information). All 2.3 mm screws are inserted using the 1.5

mm driver tip, screw sleeve and silver driver handle.

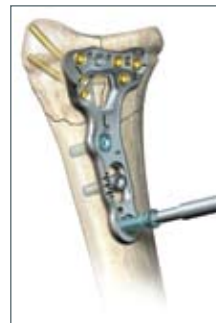**Note:** An individual Locking Drill Guide is available in the system as an alternative for drilling the distal holes. Screw length can be read using the depth probe.

## Styloid Screw Placement:

The radial styloid screws are designed to specifically target and support the radial styloid. Insert the drill guide into either styloid hole located in the dual slot on the back of the targeting guide and continue the same screw measurement and placement process for both styloid screws.



**Note:** It is recommended that the entire distal row and the two radial styloid holes be filled with screws.



## 6 PROXIMAL SCREW PLACEMENT

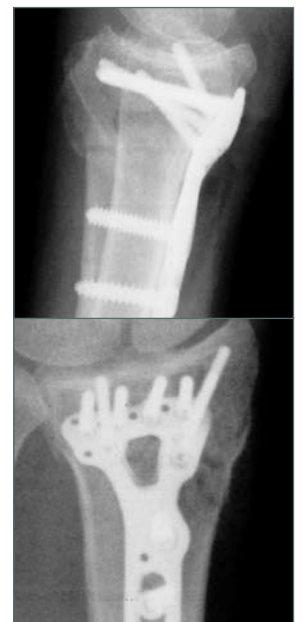Insert the threaded drill guide into the screw hole distal to the slot, drill with the 2.8 mm drill and measure with the depth gauge. Insert the proper length 3.5 mm blue locking screw using the 2.5 mm driver tip, sleeve and blue driver handle. Take care that the screw

does not exit the bone dorsally. Using the same process, drill and place the final locking screw.

## 7 CLOSING AND POST-OP PROTOCOL

Perform a thorough radiographic evaluation checking fragment reduction, alignment and screw placement. Verify that there is not a gap between the bone and the plate in the lateral view and that the distal screws have not penetrated the radiocarpal joint. Close the wound and support the wrist according to bone quality and stability.

Allow for early functional use of the hand and start immediate finger range of motion and forearm rotation postoperatively.



# Hand therapy: a valuable adjunct to hand surgery

## An introduction to the International Federation of Societies for Hand Therapy (IFSHT)

**H**and therapy is defined as the art and science of rehabilitation of the upper limb. It is a specialisation for occupational therapists or physiotherapists across the world and combines knowledge of anatomy, physiology, pathology, biomechanics and upper limb diseases and injuries. It is an integral part of hand management and serves as a valuable adjunct to hand surgery, ensuring that upper limb patients reach their full rehabilitation potential.

The International Federation of Societies for Hand Therapy was founded in Paris, France in 1986. The Federation has grown from a small organisation with six member countries to an organisation with 31 full member countries and five Corresponding

member countries. Although the Federation is a lot smaller than the IFSSH, it represents over 5000 therapists all over the world.

The main purposes of the Federation are to coordinate activities of the various societies for hand therapy and to increase and enhance the exchange of knowledge of hand therapy worldwide.

The IFSHT actively promotes the training of hand therapists the world over, so that the number of patients who receive hand rehabilitation, may increase. This in turn, will facilitate their return to normal functioning and enhance their ability to make a positive contribution to their community

Representatives from the member societies meet every three years to discuss issues of common interest and plans for the future. The promotion of high standards of care, education and research is encouraged by the attendance of the scientific meetings, which are presented every three years. When possible, these meetings are presented together with the IFSSH, to actively encourage the close cooperation between hand surgeons

and hand therapists.

Clinical practice differs widely throughout the world, as does the number of therapists who work in different countries. There are very few trained hand therapists in certain parts of the world, especially the developing countries, making it very difficult for patients to reach their full potential after injury or disease. It is for this reason that the Federation actively supports the publication of the IFSSH ezine, under the editorship of Prof Ulrich Mennen. It is an ideal opportunity for surgeons who work in areas with an undersupply of therapists, to learn more about what hand therapy can offer their patients. The IFSSH ezine will also make it possible for readers to gain direct access to the IFSHT website.

Should a hand surgeon or hand therapist have a query relating to hand therapy, they are welcome to click on the address to visit our website ([www.ifsht.org](http://www.ifsht.org)). One of the important features of the website is a database of contact details of the various member societies. This is especially helpful when looking for a hand therapist in another part of the world to take over the treatment

---

**“Hand therapy is defined as the art and science of rehabilitation of the upper limb”**



of a patient who resides in another country than where he was operated.

The IFHST is looking forward to sharing a page or two of the IFSSH ezine in future editions. The plan is to publish short articles with practical hints and tips on the management of a variety of hand conditions and injuries. It is hoped that these articles will stimulate cooperation between therapists and surgeons and especially be of value to those hand specialists (surgeons or therapists) who work in fairly isolated conditions.

Since the electronic media has ensured that communication across the

world has become easy and more or less instantaneous, dialogue between surgeons and therapists in different parts of the world will be possible. This will greatly enhance the understanding of each other's professions and ensure that the patients in our care will receive the best care possible.

The IFHST looks forward to sharing knowledge and expertise with the readers of the IFSSH ezine.

This project will be coordinated by two Past Presidents of the Federation, Maggi Persson (Sweden) and Corrienne van Velze (South Africa). They could be contacted at the following addresses:

***The IFHST executive committee:***

*President: Lynne Feehan, Canada (front middle)*

*President-elect: Sarah Ewald, Switzerland (front left)*

*Secretary-General: Ursula Wendling, Switzerland (back right)*

*Treasurer: Heidi Miettinen, Finland (front right)*

*Historian: Patricia Rappaport (back left)*

*Past President: Judy Colditz USA (back middle)*

***Maggi Persson:***

*margareta.person@artronova.se*

***Corrienne van Velze:***

*vanvelze@iafrica.com*

# Acknowledgement of Pioneers in Hand Surgery

Below you will find a write-up by Dr Alfred Swanson, at the time President of the IFSSH explaining the decision taken by the Council to honour those who have made an exceptional contribution to better manage Hand conditions. The IFSSH ezine will publish the biographical information of the pioneers in every issue going forward.

### **IFSSH Third International Congress Tokyo, Japan: November 3, 1986**

Those physicians who have specialised in Hand Surgery have fortunately come from a variety of disciplines. They have applied their knowledge and skills in general surgery, plastic surgery, orthopaedic surgery, neuro-surgery, anatomy, physiology, pediatrics, neurology, rheumatology and engineering to the diagnosis and treatment of the diseases, disorders and injuries that affect the hand. The hand separates us from lower animal species and performs the work of the human brain in all of its transactions of labor, communications, expressions performed with skill, speed, precision, power and sensitivity. The knowledge of this specialty is relatively new in the world and has reached development and dissemination through the works and contributions of many great individuals. Appropriate recognition of these persons is difficult. Listing names of those pioneers who appear in our literature has been done. Recognising those living persons who have spent their lives to further our specialty is the purpose of this presentation.

The Council of the IFSSH has reviewed and discussed a list of these important persons, and takes great pleasure in presenting them to you at this time. To recognise a Pioneer for his great contributions is enriching to all of us.

The Federation considers it most appropriate that official praise and commendation be extended

to our Pioneers in grateful recognition of their truly exemplary record of contributions to the field of Hand Surgery and to people everywhere. This occasion provides us an opportunity to recognize those who have come before us, and particularly, these gentlemen who by their wealth of discoveries and advances in Hand Surgery have so vastly improved the lives of thousands of persons the world over.

*Alfred B. Swanson, M.D.*

The following persons were the first group who were honoured as Pioneers at Hand Surgery

*Professor Tamikazu Amako*

*Paul W. Brand, C.B.E., F.R.C.S.*

*Martin A. Entin, M.D.*

*Professor Johan M. F. Landsmeer*

*J. William Littler, M.D.*

*Professor Erik Moberg*

*Professor Raoul Tubiana*

*Professor Claude Verdan*

*Joseph H. Boyes, M.D.*

*Mario Gonzalez-Ulloa, M.D.*

*Marc Iselin, M.D.*

*Sir Benjamin Rank*

*H. Graham Stack, F.R.C.S.*

*Sir Sidney Sunderland*

*Kauko J. Vainio, M.D.*


## IFSSH Pioneer profile:

### Professor Tamikazu Amako

Professor Amako was responsible for the development of the Japanese Society for Surgery of the Hand which held its first annual meeting in Kobe in July, 1957. He has also been a dynamic leader in all aspects of Orthopaedic Surgery in Japan and Asia.

Professor Amako graduated from the Kyushu Imperial University, Faculty of Medicine where he became Lecturer and then Assistant Professor in the Department of Orthopaedic Surgery. In 1936 he received "Igaku-hakase" (Ph.D). He further studied Orthopaedic Surgery in Germany and Switzerland. Following six years of military service in an Army Hospital, he was appointed Professor of Orthopaedic Surgery – first

at Niigata University, and then at Kyushu University where he later became the Dean of the School of Medicine. He was appointed member of the Committee of Exchange of Scholars, USA – Japan Scientific Corporation (1964). Professor Amako was President of many National and International Congresses, including the first meeting of the Asian Society of Plastic Surgery (1963), the International Meeting of the International Medical Society of Paraplegia (1964), the 3rd Congress of the Japanese Society of Rehabilitation Medicine (1966), the 1st Congress of the Japanese Medical Society of Paraplegia (1966),



the 12th Congress of the Japanese Rheumatism Association (1968) and 14th Congress of the International

Society of Orthopaedics and Traumatology (SICOT).

Professor Amako was President of the Japanese Orthopaedic Association (1952-53). He is an Honorary Member of the German Orthopaedic Association and an Honorary Fellow of the British Orthopaedic Association. Professor Amako was awarded the 1st Order of the Sacred Treasure by the Japanese Government in 1979.

## IFSSH Pioneer profile:

### Paul W Brand CBE, FRCS

Dr Brand has made major contributions to surgery of the paralytic patient. His scientific devoted and humanitarian work in the care of leprosy deformities in the hand and foot in Vellore, India are classical. His concern for worldwide control of Hansen's disease has continued after his relocation to the United States.

Dr Brand was born in India of missionary parents. He earned his Bachelor of Medicine and of Science degrees for the University Hospital in London, England and was a Resident Surgical Officer at the Hospital for Sick Children, London University.

Dr Brand returned to Vellore, India, where he was Professor of Orthopaedic Surgery at the Christian Medical College from 1946 to 1964, and also Dean of the Faculty of Medicine. At the University of Madras, Dr Brand was examiner in Surgery and Orthopaedic Surgery, and member of the Academic Council. He was also a member of the Review Committee of Indian Council of Medical Research and served as Medical Director of the ALERT program in Ethiopia.

Dr Brand has been Chief of the Rehabilitation Branch at the Hansen's Disease Center, Carville, Louisiana, since



1966. He is Clinical Professor of Surgery and of Orthopaedics at the Louisiana State University Medical

School, Baton Rouge, and of the Department of Physical Therapy at their School of Allied Health Profession.

His long list of honorary appointments include Consultant on Surgery and Rehabilitation to the Leprosy Mission, London, and to the American Leprosy Missions, Member of the Expert Panel of Leprosy of the World Health Organization, Consultant on Rehabilitation to the Pan American and

# Remembering our Pioneers

World Health Organisations, Member of the Medical Advisory Committee of All-African Leprosy and Rehabilitation Training Center in Ethiopia, Member of the Advisory Board of the Pan American Health Organization International Center for Training and Research in Leprosy and Related Diseases. Dr Brand was Associate Editor of the International Journal of Leprosy and Chairman of the Board of Governors of the Schieffelin Research Sanatorium in India.

Dr Brand has received many honors and distinctions for his outstanding

contributions. He was Hunterian Professor of the Royal College of Surgeons in England (1952, 1962). He received the Albert Laskar Award, was decorated 'Commander of the Order of the British Empire', has received the Medal of the American Association of Plastic Surgeons and the Founders Medal of the National Rehabilitation Association, the Gold Medal of the Swedish Red Cross, the Damien-Dutton Award, the Distinguished Service Award of the Department of Health and Human Services, Public Health Service

and has an Honorary Degree of Doctor of Laws from Wheaton College, Illinois.

Dr Brand was a Fellow of the Royal Society of Medicine, of the British Orthopaedic Association, of the Royal College of Surgeons, and of the American College of Surgeons. He was a member of numerous Orthopaedic, Hand Surgery, and Plastic and Reconstructive Surgery societies in the world. Dr Brand is the author of 58 scientific articles, 35 chapters in medical textbook and of 3 books of his own.

## The Giants Of Hand Surgery

The IFSSH acknowledges the pioneering contributions made by the following persons and are honoured with the title: Giant of Hand Surgery. This list was also presented at the Third IFSSH Congress in 1986 in Tokyo, Japan.

### 16th Century

*Ambroisè Pare*

*Felix Wurtz*

### 17th Century

*Francoise G. De Lepeyronie*

*Bernhard S. Albinus*

*Pieter Campers*

*18th Century*

*William Heberden*

*Roland Martin*

*Dominique J. Larrey*

*Sir Astley Paston Cooper*

*Abraham Colles*

*Sir Charles Bell*

*Baron Guillaume Dupuytren*

*Jacques Delpech*

### 19th Century

*Ernest Weber*

*Guillaume B.A. Duchenne*

*George F. Stromeyer*

*F. Guermontprez*

*Charles P. Denonvilliers*

*William J. Little*

*William E. Horner*

*William Adams Theodor Schwann*

*Filippo Pacini*

*Wenzel L Gruber*

*Sir. James Paget*

*Augustus Volney Waller*

*Carl Von Langer*

*P.C. Hughier*

*Alfred B. Garrod*

*Archibald E. Garrod*

*Alfred Poland*

*John R. Wolfe*

*Karl T. Thiersch*

*Johann F. A. Van Esmarch*

*Bernhard von Langenbeck*

*Henry A. Martin*

*Silas W. Mitchell George Meissner*

*Richrd von Volkmann*

*Louis Xavier E. Ollier*

*Felix J.C. Guyon*

*Johann F. Horner*

*Friedrich A Von Recklinghausen*

*Maurice Raynaud*

*Louis A. Ranvier*

*John Cleland*

*Edward H. Bennett*

*Wilhelm H. Erb*

*Francesco Parona*

*Jacques L. Reverdin*

*Friedrich S. Merkel*

*Otto W. Madelung*

*Carl Nicoladoni*

*Otto Sprengel*

*Santiago Ramóny Cajal*

*Eduard A. Albert*

*Pierre Marie*

*Charles E. Beevor*

*Henri Francois Secretan*

*Sir Robert Jones*

*Hugh Owen Thomas*

*Augusta Klumpe*

*Harold J. Stiles*

*Erich Lexer*

### 20th Century

*Eugène Apert*

*Fritz de Quervain*

*Harvey W. Cushing*

*Fritz Lange*

*O. Vulpius*

*Konrad Bielsalski*

*George C. Prthes*

*Robert Kienböck*

*Allen B. Kanel*

*Vladimir P. Filatov*

*William Darrach*

*Jules Froment*

*Arthur Steindler*

*Martin Kirshner*

*Jules Tinel*

*Sterling Bunnell*

*Harold D. Gillies*

*Leon Mayo*

*Ricardo Finochietto*

*Archibald H. McIndoe*

*Herbert Seddon*

*Fenton Braithwaite*

*Otto Hilgenfeldt*

*Frederick Wood-Jones*

*Sumner L. Koch*

*Michael L. Mason*

*Harvey S. Allen*

*Henry C. Marble*

*Hugh Auchincloss*

*Condict W. Cutler*

*Jr. Arthur Barsky*

*Emanuel B. Kaplan*

*Augusto Bonola*

*A.R. Wakefield*

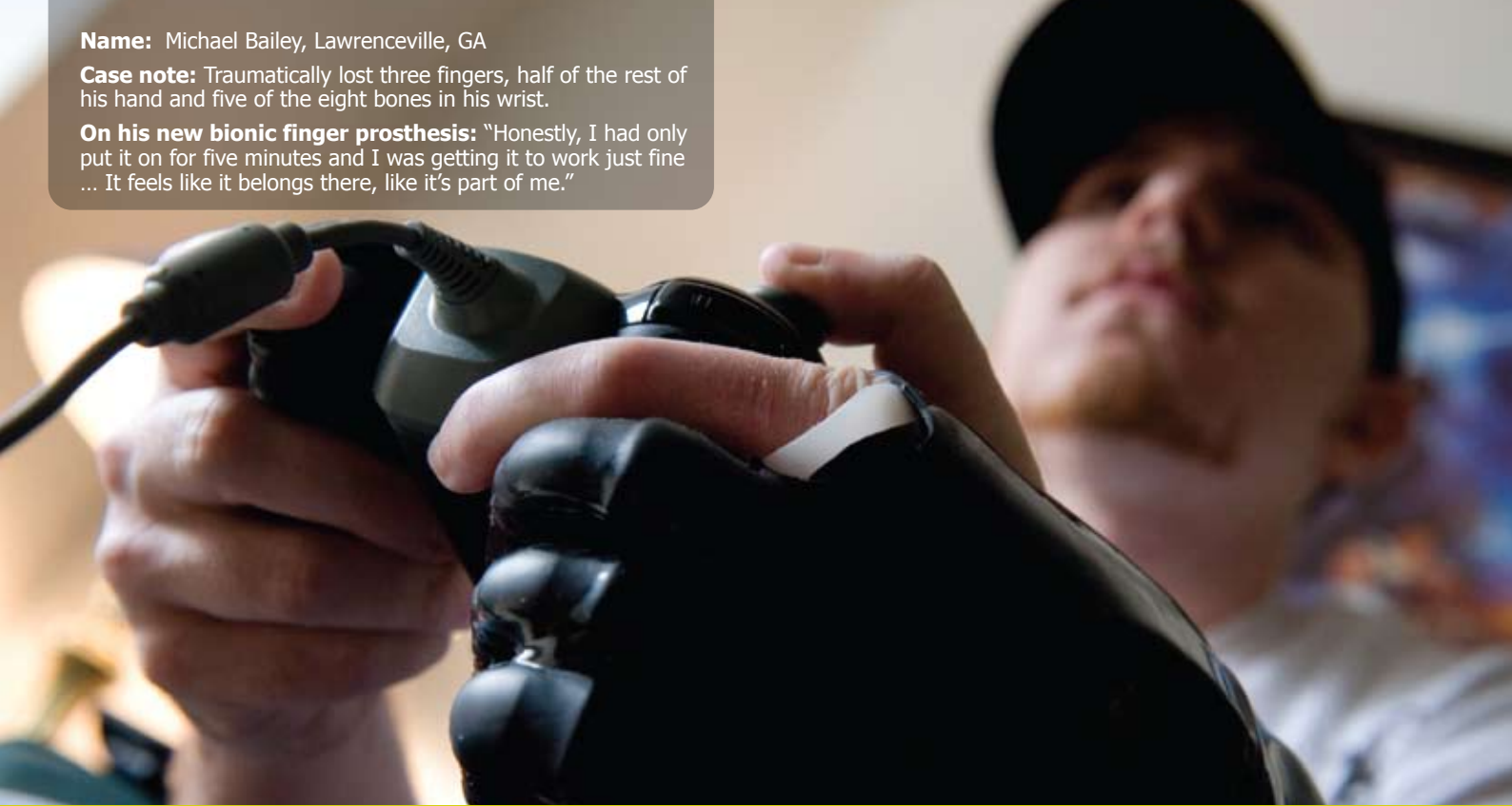
*T. Skoog*

*R. Guy Pulvertaft*

**Name:** Michael Bailey, Lawrenceville, GA

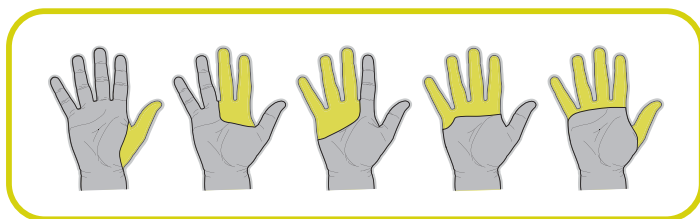
**Case note:** Traumatologically lost three fingers, half of the rest of his hand and five of the eight bones in his wrist.

**On his new bionic finger prosthesis:** "Honestly, I had only put it on for five minutes and I was getting it to work just fine ... It feels like it belongs there, like it's part of me."



## ProDigits: the world's first powered prosthetic fingers

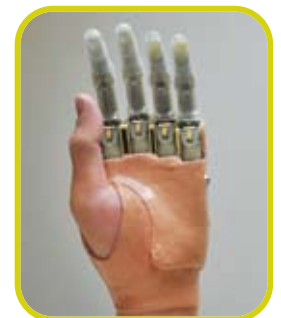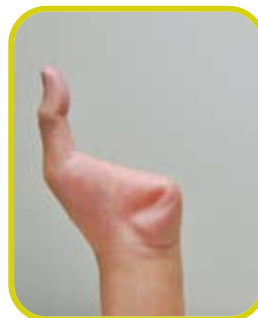- Fully customized to accommodate each patient's level of absence
- Suitable for patients missing between one and five fingers



- Provides partial hand patients with a return to function never previously available with prosthetics

### ProDigits in Practice

The photos below show a system built for a four digit amputee. This example shows an uncovered ProDigits prosthesis.



For more images and patient stories, visit [www.touchbionics.com](http://www.touchbionics.com)

Interested to know more about ProDigits? Working with a patient who may be a candidate? [Click here](#) to contact us today

# Investigation shines new light on bipolar radial head arthroplasty

## Germany

A recent study led by Dr Klaus Burkhart from the Department for Trauma Surgery, Center for Orthopaedic and Trauma Surgery, University of Cologne, Germany looked at the mid- to long term results of 19 patients who received a bipolar radial head arthroplasty. The patients were treated for reconstructive radial head fractures and were examined at a mean of 106 months following implantation.

"We have a long experience with radial head arthroplasty in our department. Although one can find many studies reporting short-term results, the long-term effects of a radial head prosthesis remain uncertain. Therefore, we wanted to evaluate the results of our first patients," Dr Burkhart explained.

The results of the study demonstrated that six patients achieved excellent results, 10 good and one fair with a mean dash score of 9.8.

According to Burkhart, a correctly implanted radial head prosthesis can work well and most of the patients yielded good to excellent objective as well as subjective results. Poor results may have been the consequence of wrong implantation e.g. overstuffing. "Overstuffing leads to increased pressure on the capitellum and may therefore constitute early degenerative changes or even capitellar erosions," he said. In his opinion, no radial head

**"The treating surgeon should be observant of any degenerative changes that might become symptomatic as radial head arthroplasty patients are young and not elderly"**

prosthesis can perfectly imitate the radial head's complex anatomy. This might be another factor promoting cartilage wear of the capitellum and proximal radioulnar joint.

In addition, the high prevalence of radiological degenerative changes seen in the cohort was another interesting point that the team noted. "Although these radiological degenerative changes were mostly asymptomatic, there is a risk that one day they will become symptomatic. We could not differentiate whether these radiological degenerative changes were the result of the initial trauma or the radial head prosthesis," he added.

Burkhart believes every hand surgeon should understand the following about this procedure: "The radial head is an important stabilizer of the elbow. Therefore, it is important to preserve or replace the radial head. Anatomical

reduction and stable fixation should be regarded as the best treatment as no prosthesis can perfectly imitate the complex anatomy and biomechanics of the radial head. Nevertheless, not every radial fracture can be fixed anatomically and stably. Our results support that radial head arthroplasty is a standard-treatment for irreconstructible radial fractures. Correct implantation is essential. Radial head arthroplasty patients should be followed up regularly. The treating surgeon should be observant of any degenerative changes that might become symptomatic as radial head arthroplasty patients are young and not elderly. Radial head resection should not be performed in an acute trauma situation."

Regarding future studies, the team is planning to reexamine the same patients. "Furthermore, we were conducting basic science studies concerning the diagnostics of overstuffing of radial head prostheses as well as the aetiology and diagnostics of Essex-Lopresti-Lesions," he concluded.

### Journal reference:

*Mid- to Long Term Results after Bipolar Radial Head Arthroplasty,*  
Burkhart KJ, Mattyasovszky SG, Runkel M, Schwarz C, Kuchle R, Hessmann MH, Rommens PM and Muller LP  
*J Shoulder Elbow Surg* 19: 965-72, 2010.  
[[http://www.jshoulderelbow.org/article/S1058-2746\(10\)00240-5/abstract](http://www.jshoulderelbow.org/article/S1058-2746(10)00240-5/abstract)]

# Corrective wrist surgery makes patients with cerebral palsy happy

## India

A study that looked at the patient satisfaction and functional and cosmetic outcome after correction of the wrist flexion deformity in cerebral palsy was led by Dr Raja Sabapathy from the Department of Plastic Surgery, Hand Surgery, Reconstructive Microsurgery and Burns at Ganga Hospital, Coimbatore in India.

"We feel that any treatment for a cerebral palsy child must make both the child and the parents or the caregiver happy. In our experience we found that after the commonly performed flexor carpi ulnaris to extensor carpi radialis brevis tendon transfer to correct wrist deformity, many parents expressed their satisfaction at the results. We wanted to find out what component of the outcome made them happy, hence the study," explained Dr Sabapathy.

Fifteen patients were reviewed after a mean follow-up of 23 months. The functional and cosmetic outcome and patient satisfaction were evaluated using patient rated scales. Fourteen out of 15 patients felt that the procedure was worthwhile and eight of them felt that the result was good or excellent. "The most interesting observation of our study was that there was a significant correlation between patient satisfaction and aesthetic outcome. As surgeons we tend to focus on functional improvement all the time when considering

**"Even when no great functional improvement is expected from surgical treatment, correcting the wrist deformity can be worthwhile because of the aesthetic improvement"**

these patients for surgery. But many patients with cerebral palsy may also be seeking treatment for aesthetic reasons. Improvement in that field could result in happy patients, who are more motivated to better use their available hand" he continued.

For Sabapathy, correction of wrist deformity in patients with cerebral palsy of upper limb is gratifying. He believes that it leads to functional and cosmetic improvement and most of the patients are better after the operation. "Even when no great functional improvement is expected from surgical treatment, correcting the wrist deformity can be worthwhile because of the aesthetic improvement. The improved appearance of the limb allows the patients to integrate better in society. Many children are able to do more with the hand



after the operation but still they may neglect the hand and only use it when encouraged to do so," he added.

"We are now performing a prospective study to analyse the pre-operation and post-operation functional status and overall improvement after surgery for thumb deformity in cerebral palsy. We will also try to analyse the patient-parent satisfaction of this procedure," he concluded.

### Journal reference:

*The relation of patient satisfaction and functional and cosmetic outcome after correction of the wrist flexion deformity in cerebral palsy*

K. Libberecht, S. R. Sabapathy, P. Bhardwaj

*J Hand Surg Eur Vol February 2011 vol. 36 no. 2 141-146*

[<http://jhs.sagepub.com/content/36/2/141.abstract>]

Below is a selection of contents pages from the latest issues of the following leading hand surgery journals. Hover your mouse over each article heading and click to go to the original abstract page of the article

## Journal of Hand Surgery: American volume Vol 36 | No. 7 | July 2011 | Pages 1131-1266



- Open Fractures of the Distal Radius: The Effects of Delayed Debridement and Immediate Internal Fixation on Infection Rates and the Need for Secondary Procedures. John C. Kurylo, Thomas W. Axelrad, Paul Tornetta, Andrew Jawa
- Complications of Low-Profile Dorsal Versus Volar Locking Plates in the Distal Radius: A Comparative Study. Yangyang R. Yu, Melvin C. Makhni, Shervin Tabrizi, Tamara D. Rozental, et al.
- Effect of Facility on the Operative Costs of Distal Radius Fractures. Richard C. Mather, Robert W. Wysocki, J. Mack Aldridge, Ricardo Pietrobon, et al.
- Comparison of Radiographic Stress Views for Scapholunate Dynamic Instability in a Cadaver Model. Steve K. Lee, Healthy Desai, Benjamin Silver, Gurpreet Dhaliwal, et al.
- Computed Tomography

- Osteoabsorptiometry Alterations in Stress Distribution Patterns Through the Wrist After Radial Shortening Osteotomy for Kienböck Disease. Hikaru Makabe, Norimasa Iwasaki, Tamotsu Kamishima, Naomi Oizumi, et al.
- Radiographic Laxity of the Trapeziometacarpal Joint Is Correlated With Generalized Joint Hypermobility. Jennifer Moriatis Wolf, Star Schreier, Scott Tomsick, Allison Williams, et al. [http://www.jhandsurg.org/article/S0363-5023\(11\)00353-4/fulltext](http://www.jhandsurg.org/article/S0363-5023(11)00353-4/fulltext)
- Capsular Imbrication for Posttraumatic Instability of the Distal Radioulnar Joint. Stefanie Manz, Maya B. Wolf, Franck Marie Leclère, Peter Hahn, et al.
- Posttraumatic Reconstruction of the Hand—A Retrospective Review of 87 Toe-to-Hand Transfers Compared With an Earlier Report. Hebe D. Kvernmo, Tsu-Min Tsai
- Dorsal Approach in Transfer of the Distal

- Spinal Accessory Nerve Into the Suprascapular Nerve: Histomorphometric Analysis and Clinical Results in 14 Cases of Upper Brachial Plexus Injuries. Prem S. Bhandari, Prabal Deb
- Semmes-Weinstein Monofilaments: Influence of Temperature, Humidity, and Age. Max H. Haloua, Inger Sierevelt, Willem J. Theuvenet
- Typical Brachial Neuritis (Parsonage-Turner Syndrome) With Hourglass-Like Constrictions in the Affected Nerves. Yong-wei Pan, Shufeng Wang, Guanglei Tian, Chun Li, et al.
- Flexor Tendon Repair With a Knotless Barbed Suture: A Comparative Biomechanical Study. Ian C. Marrero-Amadeo, Aakash Chauhan, Stuart J. Warden, Gregory A. Merrell

## Journal of Hand Surgery: Asian Volume Volume: 16, Issue: 2



- Functional And Morphological Effects Of Indirect Gradual Elongation Of Peripheral Nerve: Electrophysiological And Morphological Changes At Different Elongation Rates. Shigeki Kubota, Yasumasa Nishiura, Yuki Hara, Saijilafu, Ichiro Abe and Naoyuki Ochiai
- Reoperation For Metalwork Complications Following The Use Of Volar Locking Plates For Distal Radius Fractures: A United Kingdom Experience. A. Sahu, C. P. Charalambous, S. P. Mills, S. Batra and M. J. Ravenscroft
- Long Term Results Of Matched Hemiresection Interposition Arthroplasty For Druj Arthritis In Rheumatoid Patients. Syed Kamran Ahmed, Jason Pui Yin Cheung, Boris Kwok-Keung Fung and Wing-Yuk Ip

- Arthroscopic Assisted Bone Grafting For Early Stages Of Kienböck's Disease. L. Pegoli, A. Ghezzi, E. Cavalli, R. Luchetti and G. Pajardi.
- An Inverting Circumferential Suture For Flexor Tenorrhaphy P. J. Sullivan, K. M. Hirpara, C. E. Healy, P. Dockery and J. L. Kelly
- Intramedullary fixation of proximal phalangeal fractures through a volar extra-tendon sheath approach. Eichi Itadera, Yasuhiro Oikawa, Masataka Shibayama, Tomoko Kobayashi and Hideshige Moriya
- Giant Cell Tumours Of Tendon Sheath Of Hand: Causes And Strategies To Prevent Recurrence. Azal Jalgaonkar, Baljinder Dhinsa, Howard Cottam and Ganapathyraman Mani

### Case Reports:

- Early Combined Neurosurgery And Orthopaedic Surgery In Neonatal Brachial Plexus Palsy Ram Palti, Maxim D. Horwitz, Nicholas C. Smith and Michael A. Tonkin
- Surgical Treatment Of Neurogenic Thoracic Outlet Syndrome Secondary To The Clavicle Haematogenic Subacute Osteomyelitis. Martins Kapickis, Amitabha Lahiri and Guntars Pupelis
- Permanent Ulnar Nerve Palsy After Embolotherapy Of Arteriovenous Malformation Around The Elbow Chul-hyun Cho and Jin-soo Choi
- Spontaneous Partial Posterior Interosseous Nerve Palsy Not Caused By An Adjacent Ganglion Jacqueline Siau Woon Tan and

## Journal of Hand Therapy Volume. 24, No. 3 - July 2011



- A Randomized Clinical Controlled Study Comparing the Effect of Modified Manual Edema Mobilization Treatment with Traditional Edema Technique in Patients with a Fracture of the Distal Radius. Karin Knygsand-Roehoej, Thomas Maribo.
- Dynamic Splinting for the Stiff Hand after Trauma: Predictors of Contracture Resolution. Celeste Glasgow, Leigh R. Tooth, Jenny Fleming, Susan Peters
- Muscle Activation during Hand Dexterity Tasks in Women with Hand Osteoarthritis and Control Subjects. Kristina M. Calder, Victoria Galea, Jean Wessel, Joy C. MacDermid, Norma J. MacIntyre
- Comparison of Two Carpometacarpal Stabilizing Splints for Individuals with Thumb Osteoarthritis. Helia Sillem, Catherine L. Backman, William C. Miller, Linda C. Li

- Clinical Commentary in Response to: Comparison of Two Carpometacarpal Stabilizing Splints for Individuals with Thumb Osteoarthritis. Virginia H. O'Brien
- Static Versus Dynamic Splinting for Proximal Interphalangeal Joint Pyrocarbon Implant Arthroplasty: A Comparison of Current and Historical Cohorts. Jeanne M. Riggs, Angela K. Lyden, Kevin C. Chung, Susan L. Murphy
- Progress in Vibrotactile Threshold Evaluation Techniques: A Review. Minu Shikha Gandhi, Richard Seseck, Robert Tuckett, Stacy J. Morris Bamberg

- Upper Extremity Function in Stroke Subjects: Relationships between the International Classification of Functioning, Disability, and Health Domains. Iza Faria-Fortini, Stella Maris Michaelsen, Janine Gomes Cassiano, Luci Fuscaldi Teixeira-Salmela
- A Test Case: Does the Availability of Visual Feedback Impact Grip Strength Scores When Using a Digital Dynamometer? Gwen Weinstock-Zlotnick, Jane Bear-Lehman, Tzu-Ying Yu

Andrew Kean Tuck Yam

- Volar Radiocarpal Dislocation: Case Report And Review Of Literature Kiran Singiseti, Michalopoulos Konstantinos and Alan Middleton
- Ulnar-Sided Wrist Pain Due To Isolated Disk Tear Of Triangular Fibrocartilage Complex Within The Distal Radioulnar Joint: Two Case Reports Yukio Abe and Yasuhiro Tominaga
- Osteochondroma Of The Lunate With Extensor Tendons Rupture Of The Index Finger: A Case Report Takeshi Katayama, Hiroshi Ono and Kazuhiro Furuta
- Severe Isolated Trapezoid Fracture: A Case Report M. L. W. Kam, S. Sreedharan, L. C. Teoh and W. Y. C. Chew
- Post-Traumatic Combined Flexion Of The Thumb, Index And Middle Finger After Intrinsic Muscles Reconstruction Of The Hand: A Case Report Stefano Lucchina,

Alexandru Nistor and Cesare Fusetti

- Spontaneous Ulnar Dislocation Of The Index, Long, Ring And Small Finger Extensor Tendons At The Metacarpophalangeal Joints: A Case Report Katsuhisa Tanabe, Takaya Nakajima and Eiji Sogo
- Locked Metacarpophalangeal Joint Of The Little Finger Due To Hyperextension Injury: A Case Report Masayoshi Ikeda, Yuka Kobayashi, Ikuo Saito and Yoshinori Oka
- Malignant Transformation Of An Enchondroma Of The Hand: A Case Report H. Ozcanli, E. Alimoglu and A. T. Aydin
- Avulsion Of Flexor Digitorum Profundus Secondary To Recurrent Enchondroma T. Nomura, T. Nakamura, K. Sato, Y. Toyama and H. Ikegami
- Outcome Of Reconstruction For Duplication Of The Thumb In Adults Aged Over 40 A. Manohar and A. J. Beard

### Surgical Techniques:

- Bipartite distal phalanx — watch out for this condition! Asif Bhatti and Sunil Thirkannad
- Osteocutaneous Radial Forearm Free Flaps: Prophylactic Fixation Of Donor Site Using Locking Plate Augmented With Mineral Cement F. Ya'ish, A. Waton, H. B'Durga and A. Nanu
- Fixation Of Comminuted Distal Radius Fractures With A Mixture Of Calcium Phosphate And Calcium Sulfate Cement Mario G. Solari, Emily Spangler, Andrew Lee and Ronit Wollstein
- Use Of A Hand Drill To Remove Particulate Contamination Within A Traumatic Bone Tunnel Pei Yein Tong, Andre E. J. Cheah and Yeong Pin Peng <http://www.worldscinet.com/hs/16/1602/S0218810411005424.html>

## Journal of Hand Surgery: European Volume **J Hand Surg Eur Vol July 2011; 36 447 – 524**



- The middle radioulnar joint and triarticular forearm complex. M. Soubeyrand, V. Wassermann, C. Hirsch, C. Oberlin, O. Gagey, and C. Dumontier
- Randomized controlled trial of the application of topical b-FGF-impregnated gelatin microspheres to improve tissue survival in subzone II fingertip amputations Hirohisa Kusuhara, Yoshihito Itani, Noritaka Isogai, and Yasuhiko Tabata
- Biomechanical evaluation of the Pulvertaft versus the 'wrap around' tendon suture technique S. P. Fuchs, E. T. Walbeehm, and S. E. R. Hovius
- Active mobilisation following single cross grasp four-strand flexor tenorrhaphy (Adelaide repair) M. J. Sandow and M. McMahon
- How much does a pennington lock add to strength of a tendon repair? Y. F. Wu and J. B. Tang
- A New Surgical Approach To Dupuytren's Disease I. Edmunds and C. Chien
- Keloid Formation After Syndactyly Release In Patients With Associated Macroductyly: Management With Methotrexate Therapy S. K. Tolerton and M. A. Tonkin
- Displaced Scaphoid Waist Fractures: The Use Of A Week 4 Ct Scan To Predict The Likelihood Of Union With Nonoperative Treatment R. Amirfeyz, A. Bebbington, N. D. Downing, J. A. Oni, and T. R. C. Davis
- Radioulnar Laxity And Clinical Outcome Do Not Correlate After A Distal Radius Fracture J. H. Scheer and L. E. Adolfsson
- Low-Profile Plate Fixation In Arthrodesis Of The First Metacarpophalangeal Joint C. Rasmussen, S. Roos, and M. Boeckstyns
- The Krukenberg procedure revisited. Niroshan Sivathanan, Sasanka Sekhar Chatterjee and Abhilash Jain
- Scaphoid fracture with an associated dorsal lip of lunate fracture – a sign of instability? A. M. Imbuldeniya and J. C. Compson
- Koebner phenomenon following steroid injection for trigger finger. H Dowlen and K Owers
- The absence of palmaris longus tendon and its contribution to pinch strength in the Anatolian population. K Ertem, Y. Karakoc, and D. Pepele
- How to prevent the avulsed soft tissues from wrapping around the K-wire. Bulent Ozcelik, Onur Egemen, and Bulent Sacak
- Novel method for wound exposure using a sutureless, self-retaining system Y. S. Lau and A. G. Perks
- Intraosseous xanthoma of the hand without an underlying lipid disorder A. Mohan, A. Jalgaonkar, and T. W. Briggs
- Is ultrasound indicated in the diagnosis of closed avulsion injuries of the flexor digitorum profundus tendon? D. A. Leonard, L. Damkat-Thomas, and H. G. Lewis

## Journal of Brachial Plexus and Peripheral Nerve Injury **6:1 – 6:3 June – July 2011**



- Prevalence of accessory deep peroneal nerve in referred patients to an electrodiagnostic medicine clinic . Seyed Rayegani, Elham Daneshlab, Mohamad Bahrami, Dariush Eliaspour, Seyed Raeissadat, Sajjad Rezaei, Marzieh Babae
- Results and current approach for Brachial Plexus reconstruction Jayme A Bertelli, Marcos F Ghizoni. <http://www.jbppni.com/content/6/1/2/abstract>
- Variations in branching of the posterior cord of brachial plexus in a Kenyan population. Johnstone M Muthoka, Simeon R Sinkeet, Swaleh H Shahbal, Ludia C Matakwa, Julius A Ogeng'

# Product News

## Hand plating system

*Osteomed*

OsteoMed's hand plating system (HPS) is designed to provide the surgeons with a comprehensive internal bone fixation system for treatment of the hand and wrist. The system, including 1.2mm, 1.6mm, 2.0mm, 2.4mm, and cannulated modules, allows you to make treatment decisions based on the presenting fracture.

The proprietary angled-locking technology incorporates cross-linked threads on the head of the screw and the interior of the plate hole along with different grades of titanium, resulting in a unique, strong and rigid construct. Both locking and non-locking screws can be used in locking plate holes, allowing for inter-operative flexibility. Multiple plate and screw configurations are available, including variable angle locking up to 22 degrees in the 1.6mm plates, allowing for anatomic reconstruction of unique fracture patterns.

Along with the variety of plates, hps provides fracture specific solutions, including the patented subcondylar plate. The subcondylar plate has a distinctive 12-degree bend to fixate condylar fractures

without obstructing joint ligaments. HPS is the first system to include a cannulated screw module and the opportunity to use cannulated headed screws in a hand plate for precise and stable screw positioning.

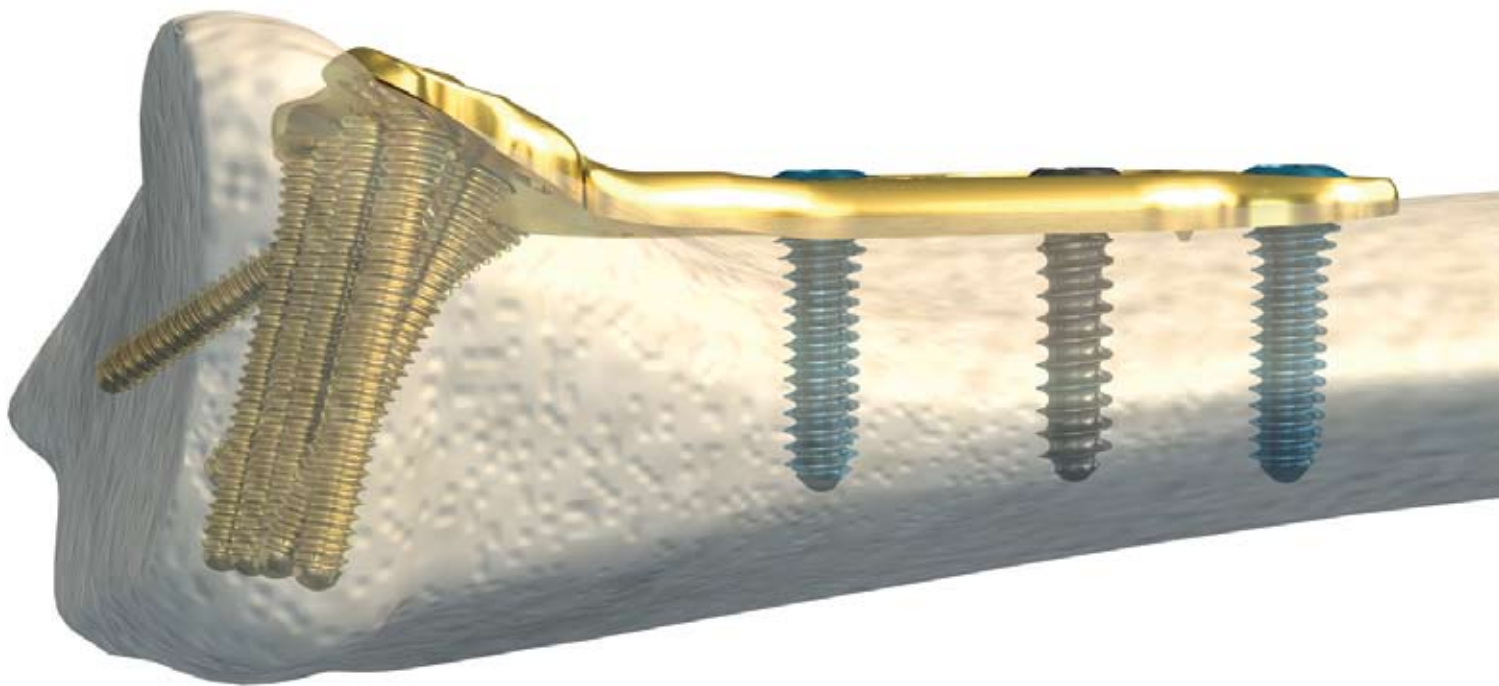
The HPS plates are highly polished to reduce surface microroughness. Decreasing surface microroughness or the size range of plate microdiscontinuities reduces tissue adhesions.\* In addition, the rounded edges and low profile of the plates and screw heads promote tendon motion and minimize irritation.

HPS offers precise instrumentation for each step of the procedure, from bone and soft tissue instrumentation to driver sleeves that aid in screw insertion and tissue protection. Unique instrumentation, including an exclusive plate cutter which cuts at a radius and prevents sharp burs on the superior surface, facilitates fracture fixation.

HPS, a versatile solution for your complex fractions!

*\* Herren DB, Nagy L, Campbell DA (eds): Osteosynthesis in the Hand: Current Concepts, FESSH Instructional Course 2008. Basel, Karger, 2008, pp 20-30*





## Acu-Loc® 2

Acumed

Developed in conjunction with our accomplished surgeon design team, Acumed® introduces the Acu-Loc® 2 Volar Distal Radius (VDR) Plating System as the next generation in plating fixation. The system presents several new plate options, a unique two piece locking compression screw, innovative instrumentation for fracture management and improved plate placement tools.

Two Plate Families give the surgeon the ability to choose between distally or proximally fitting plates. The anatomically designed Acu-Loc® 2 VDR Plate families assist in restoring the original geometry of the patient's anatomy. Our goal was to design a plate system that closely replicates the anatomical contours of the distal radius in order to maximize support and accurately reduce the

fracture. The Acu-Loc® 2 Proximal VDR Plate family was designed to provide maximum support for the articular surface from a more proximal placement.

Optimized Plate Design allows for ideal support of the radial and intermediate distal radius columns. Converging ulnar screws, new suture and additional K-wire holes were added to all plates for improved support of the volar ulnar lip and lunate facet. The plate window offers fracture visualization as well as access to metaphyseal comminution, utilizing the Fragment Reduction Tool for articular reconstruction.

Advanced Instrumentation helps with plate placement and fracture reduction. New tools such as the plate positioning handle and radiolucent targeting guides with

embedded radiopaque positioning posts help guide the surgeon during plate placement. For support with corrective osteotomies, KickStand Posts aid in plate angulation relative to the dorsally displaced distal radius.

Two-Piece Compression Screw Technology is designed to reduce difficult dorsal fragments. The Frag-Loc® is a revolutionary two-piece locking fixation device that provides compression between dorsal and volar fracture fragments through a small dorsal incision.

**[www.acumed.net](http://www.acumed.net)  
(888) 627-9957**

